

SHORT REPORT

Open Access



# Concurrent therapy with immune checkpoint inhibitors and TNF $\alpha$ blockade in patients with gastrointestinal immune-related adverse events

Yousef R. Badran<sup>1,2</sup>, Justine V. Cohen<sup>2,3</sup>, Priscilla K. Brastianos<sup>2,3</sup>, Aparna R. Parikh<sup>2,3</sup>, Theodore S. Hong<sup>2,4</sup> and Michael Dougan<sup>2,5\*</sup> 

## Abstract

**Background:** Immune checkpoint inhibitors (ICI) have demonstrated remarkable efficacy as cancer therapeutics, however, their use remains limited due to the development of immune related adverse events (irAEs). Immune related enterocolitis (irEC) is among the most common severe irAEs leading to the discontinuation of ICIs. Inhibitors of tumor necrosis factor alpha (anti-TNF $\alpha$ ) have been used to treat irEC. Recent animal studies have shown that concurrent treatment with anti-TNF $\alpha$  and ICIs improves tumor responses and decreases colitis severity. This approach has not yet been studied in prospective trials in humans. Here we describe, for the first time, the outcomes of patients who were treated concurrently with anti-TNF $\alpha$  and one or two ICIs.

**Case presentations:** Five patients with different primary malignancies were treated with ipilimumab/nivolumab (2 patients), pembrolizumab (1 patient), ipilimumab (1 patient), or cemiplimab (1 patient). All patients developed irEC within 40 days of their first ICI dose. The patients presented with a combination of upper and lower gastrointestinal symptoms and subsequently underwent upper endoscopy and/or lower endoscopy. Endoscopy results demonstrated a spectrum of acute inflammatory changes across the gastrointestinal tract. Steroid therapy was used as first line treatment. To prevent prolonged steroid use and recurrence of gastrointestinal inflammation after resumption of cancer therapy, patients were treated concurrently with infliximab and ICI. Patients tolerated further ICI therapy with no recurrence of symptoms. Repeat endoscopies showed resolution of acute inflammation and restaging imaging showed no cancer progression.

**Conclusions:** Concurrent treatment with anti-TNF $\alpha$  and ICI appears to be safe, facilitates steroid tapering, and prevents irEC. Prospective clinical trials are needed to assess the outcomes of this treatment modality.

**Keywords:** Checkpoint inhibitor, PD-1, CTLA-4, TNF $\alpha$ , Infliximab, Immune related enterocolitis, Immune related adverse events

\* Correspondence: [mldougan@partners.org](mailto:mldougan@partners.org)

<sup>2</sup>Harvard Medical School, Boston, MA 02115, USA

<sup>5</sup>Division of Gastroenterology, Department of Medicine, Massachusetts General Hospital, Boston, MA 02114, USA

Full list of author information is available at the end of the article



## Background

Monoclonal antibodies targeting the immune regulatory “checkpoint” receptors programmed death receptor 1 (PD-1), its ligand, PD-L1, and cytotoxic T cell associated antigen 4 (CTLA-4) have demonstrated remarkable efficacy against advanced cancers [1]. The natural roles of these immune checkpoints include preventing T cell over-activation, inducing anergy, maintaining peripheral immune tolerance, and contributing to T cell exhaustion in local inflammatory environments [2, 3]. By inhibiting these regulatory receptors, immune checkpoint inhibitors (ICIs) boost the anti-tumor effector functions of T cells [2]. Simultaneously, ICI-induced loss of tolerance leads to off-target immune related adverse events (irAEs) [4]. The frequency and severity of these events are an important limitation of immunotherapy, leading to treatment interruption and even discontinuation [5].

Immune related (entero) colitis (irEC) is among the most common severe irAEs leading to the discontinuation of immunotherapy [6–9]. High dose glucocorticoids are the first line management of immune mediated enterocolitis [10–13]. Current guidelines recommend continuation for at least 4 to 6 weeks after resolution of irEC [10–13]. Not infrequently, patients are intolerant to steroid tapers or require prolonged courses of glucocorticoids for symptom control. Prolonged use of glucocorticoids is associated with multiple complications that include serious infections, hyperglycemia, osteoporosis, and altered mental status. In patients with irEC who fail steroid tapers or are steroid unresponsive, inhibitors of tumor necrosis factor alpha (anti-TNF $\alpha$ ) have been used to suppress mucosal inflammation [14, 15]. Retrospective studies of patients who received anti-TNF $\alpha$  agents for irEC have shown that compared to steroids, these agents lead to more rapid symptomatic improvement and a shorter duration of steroids without affecting time to ICI treatment failure or overall survival [6, 14–16]. For patients who require anti-TNF $\alpha$  agents to control irEC, ICIs are generally discontinued out of concern for recurrent, potentially treatment refractory, colitis. Recent work in mouse models of cancer has shown that co-administration of ICI and anti-TNF $\alpha$  upfront led to improved tumor responses and decreased colitis severity, an approach that has not yet been studied in prospective trials in humans [17, 18]. In this report, we present our institutional experience on patients with different malignancies who were treated concurrently with anti-TNF $\alpha$  and single or combination ICIs.

## Patients and methods

Included in this series are patients evaluated and treated at the Massachusetts General Hospital who were referred to the gastroenterology service for new gastrointestinal complaints (abdominal pain, protracted nausea

and vomiting, or diarrhea) that arose during treatment with one or more ICIs. ICIs were administered as standard-of-care or as a part of a clinical trial. Details of the patients’ medical history, malignancy, and prior cancer therapeutics were reviewed in the chart. Data pertaining to ICI use and irEC development and management include doses of ICI, presenting grades of diarrhea and colitis, glucocorticoid dose and number of steroid taper attempts, infliximab dose and frequency, doses of infliximab to clinical remission, and doses of ICI concurrently administered with infliximab. Diarrhea and colitis were graded using the Common Terminology Criteria for Adverse Events (CTCAE) version 5.0 at disease onset [19]. Upper endoscopy and/or colonoscopy/flexible sigmoidoscopy were performed as clinically indicated at the Massachusetts General Hospital Endoscopy Unit. Consent was obtained from all patients. Pathology was reviewed by board certified pathologists. Radiologic imaging data were obtained as indicated by the treatment protocol. This retrospective study was approved by the institutional review board of the Massachusetts General Hospital.

## Results

### Patient 1

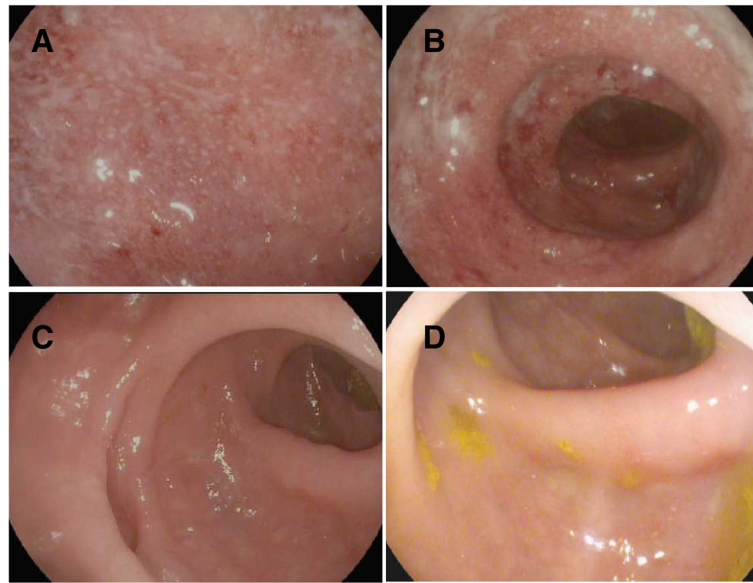
Patient 1 is a 70-year-old man with a past medical history of segmental colitis associated with diverticulosis (SCAD) who was diagnosed at the age of 73 with a right vestibular schwannoma and a large bifrontal atypical meningioma. At diagnosis, he was treated with subtotal resection and postoperative proton therapy. Two years later, he presented with recurrent bitemporal extra-cranial soft tissue meningioma treated with resection and radiation therapy. He was then started on pembrolizumab (PD-1 inhibitor) monotherapy and received two doses (Table 1). After receiving his second dose of pembrolizumab, he developed intermittent rectal bleeding without urgency, diarrhea, abdominal pain, cramping or bloating. He underwent a colonoscopy that showed endoscopic and histologic features of active colitis (Fig. 1). Based on these findings, he was treated with prednisone 60 mg, azithromycin, and metronidazole for a 7-day course that led to symptomatic improvement. With tapering of the steroids, his rectal bleeding recurred which prompted a repeat flexible sigmoidoscopy that demonstrated persistent inflammation. He then received infliximab (5 mg/kg) concurrently with prednisone 50 mg which led to resolution of his symptoms after one infusion and successful rapid tapering of prednisone. Staging imaging after 2 months off pembrolizumab therapy (due to irEC) showed progression of his intracranial tumor and extracranial metastases. After an interruption of ICI for 4 months, it was decided to restart pembrolizumab with concurrent infliximab therapy. He subsequently received a total of twelve doses of

**Table 1** Patient characteristics, ICI treatment history, symptomatology, and endoscopy findings

Patient	Age	Sex	Malignancy	History of other ICI exposure	ICI type and dose	Days (doses) to onset of symptoms post ICI	Diarrhea grade	Other symptoms	Colitis grade	Endoscopic features	Histopathologic features
1	75	M	Meningioma	None	Pembrolizumab Dose: 3 mg/kg Frequency: every 3 weeks	39 days (2)	1	None	2	Colonoscopy: Sigmoid colon: localized moderate inflammation characterized by altered vascularity, congestion (edema), friability and granularity	Colonoscopy: - Ileum: mucosa with hyperplastic Peyer's patches and no diagnostic abnormality - Ascending colon: mucosa with lymphoid aggregate and no diagnostic abnormality - Sigmoid colon: moderately active colitis with neutrophilic cryptitis and crypt abscesses
2	58	F	Colon	- Pembrolizumab (stopped 2 years prior to current ICI): no adverse effects but disease progression	Ipilimumab/ Nivolumab Dose: Ipilimumab-1 mg/kg, Nivolumab- 240 mg (3 mg/kg) Frequency: combined every 6 weeks (4 doses total) followed by nivolumab alone every 2 weeks	8 days (1)	2	Abdominal pain	2	Upper endoscopy: - Gastric antrum: diffuse moderately erythematous mucosa without bleeding - Duodenum: an acquired benign-appearing, intrinsic moderate stenosis in the first portion of the duodenum	Upper endoscopy: - Gastric antrum/fundus/body: active chronic gastritis - Duodenum: mucosa with ulceration, crypt dropout, marked expansion of lamina propria with prominent eosinophils and acute inflammation - Duodenal stricture: mucosa with mild expansion of the lamina propria
3	70	F	Melanoma	- PD-L1 inhibitor (as a part of a clinical trial): for a total of 1 year (stopped 3 years prior to current ICI). No adverse events but disease recurrence - Pembrolizumab: 200 mg 3 (mg/kg) every 3 weeks for total of 8 doses (stopped 1 year prior to current ICI); no adverse events but disease progression	Ipilimumab Dose: 3 mg/kg Frequency: every 3 weeks	35 days (2)	2	Nausea, vomiting	2	Upper Endoscopy: - Stomach: normal - Duodenum: diffuse moderately scalloped mucosa Flexible Sigmoidoscopy: - Colon: examined portion was normal	Upper Endoscopy: - Duodenum: diffuse active duodenitis with villous blunting, expansion of the lamina propria with mixed inflammation, and reactive epithelial changes - Stomach: antral mucosa with edema and mild patchy inflammation Flexible Sigmoidoscopy: - Colon: normal
4	73	M	Melanoma	Atezolizumab (in combination with cobimetinib): total of 13 cycles (stopped 2 weeks prior to current ICI)	Ipilimumab/ Nivolumab Dose: Ipilimumab-3 mg/kg, Nivolumab-1 mg/kg Frequency: combined every 3 weeks	11 days (1)	2	Nausea, vomiting, abdominal pain	2	Upper Endoscopy: - Stomach: non-bleeding erosive gastropathy - Duodenum: diffuse mildly congested mucosa without active bleeding Colonoscopy: - Sigmoid and descending colon: discontinuous areas of nonbleeding ulcerated mucosa with no stigmata of recent	Upper Endoscopy: - Stomach: active gastritis with small stromal granuloma in antrum. Active gastritis with stromal histiocytes in the body - Duodenum: active duodenitis with villous injury Colonoscopy: - Descending colon: focal active colitis with stromal histiocytes - Colon and sigmoid ulcers: severely active colitis with

**Table 1** Patient characteristics, ICI treatment history, symptomatology, and endoscopy findings (Continued)

Patient	Age	Sex	Malignancy	History of other ICI exposure	ICI type and dose	Days (doses) to onset of symptoms post ICI	Diarrhea grade	Other symptoms	Colitis grade	Endoscopic features	Histopathologic features
5	79	F	SCC	None	Cemiplimab Dose: 350 mg Frequency: every 3 weeks	14 (1 dose)	1	Nausea, vomiting	2	bleeding Upper Endoscopy: - Stomach: Non-bleeding erosive gastropathy - Duodenum: normal Flexible Sigmoidoscopy: - Colon: Inflammation characterized by congestion (edema), erythema and granularity	ulceration Upper Endoscopy: - Stomach: reactive gastropathy and intestinal metaplasia - Duodenum: normal Flexible Sigmoidoscopy: - Colon: mucosa with mildly increased cellularity of the lamina propria and epithelial injury. Focal acute inflammation is also noted, but there is no increase in apoptosis.



**Fig. 1** Infliximab and pembrolizumab for segmental colitis in meningioma. **a – d** (Images taken from the sigmoid colon during endoscopic evaluation. **a** Diagnosis of recurrent SCAD. **b** After completion of antibiotics and on prednisone. **c** Infliximab and prednisone co-treatment. **d** Infliximab and pembrolizumab co-treatment

pembrolizumab concurrently with infliximab (5mg/kg every 6 weeks, Table 2) over the course of 10.5 months. He did not experience any other irAEs or worsening rectal bleeding and a repeat flexible sigmoidoscopy showed mild active chronic colitis. Staging scans at that point showed stable intracranial and extracranial disease. Then, he developed *Clostridium difficile* colitis. He was treated with oral vancomycin to which he appropriately responded. However, after a few days of normal bowel movements, he started having loose bloody bowel movements and abdominal pain prompting an admission to the hospital. During that admission, he tested negative for *Clostridium difficile* and underwent a flexible sigmoidoscopy that showed severe colonic inflammation thought to be due to irEC. He received vancomycin, high dose intravenous steroids followed by oral steroids, and one infusion of infliximab (10 mg/kg) leading to symptom improvement. His steroids were tapered but therapy with pembrolizumab was discontinued. One month later, he developed retroperitoneal bleeding and was transitioned to hospice care.

#### Patient 2

Patient 2 is a 58-year-old woman with stage 4 microsatellite instability (MSI) high colon cancer who was diagnosed at the age of 50. At diagnosis, she underwent a right total colectomy and was treated with 12 cycles of folinic acid, fluorouracil and oxaliplatin (FOLFOX). Two years later she was found to have metastatic disease in the ovaries and underwent bilateral salpingo-oophorectomy. This was followed by 18 cycles of folinic acid, fluorouracil,

irinotecan hydrochloride, and avastin (FOLFIRI/Avastin) for metastatic foci in the abdomen. Subsequently she was treated with pembrolizumab for a total of 5 months without adverse events but then stopped due to disease progression. She underwent cytoreductive surgery (CS) with hyperthermic intraperitoneal chemotherapy (HIPEC). Afterwards, she was on two clinical trials using targeted therapies for advanced colon cancer but had no response to therapy. She then entered a clinical trial testing combination therapy with ipilimumab (CTLA-4 inhibitor), nivolumab (PD-1 inhibitor), and radiation therapy. Eight days after receiving the first dose, she developed epigastric pain, grade 2 diarrhea, abdominal distention, urgency, and stomatitis. She underwent an upper endoscopy that showed active chronic gastritis and a duodenal stricture with active duodenal inflammation (Table 1). Based on these findings, she was initially treated with prednisone 60 mg that was tapered successfully and her ICIs were held for a total of 7 weeks. Due to fear of recurrent duodenitis and the need for continued immunotherapy for disease control she was treated with infliximab (5 mg/kg every 4 weeks, Table 2) and continued to receive three further doses of ipilimumab/nivolumab then biweekly nivolumab. Over the past 7.5 months of concurrent therapy, she has had no further sustained diarrhea and only had occasional episodes of epigastric abdominal pain and nausea. She developed no other irAEs. A follow up upper endoscopy showed improvement of the inflammatory findings (Table 2). Staging imaging for colon cancer showed stable disease without further progression.

**Table 2** IrEC management and outcomes

Patient	ICI type/dose	Initial management	Number of steroid tapering attempts	Infliximab Dose-frequency	Doses of infliximab to clinical remission	Doses of ICI concurrently administered with infliximab	Follow up endoscopy on concurrent treatment (months)	Recurrence	# of months of follow-up on ICI/on concurrent therapy	Disease progression/ Follow up
1	Pembrolizumab Dose: 3 mg/kg Frequency: every 3 weeks	Prednisone 40 mg > 60 mg PO daily> taper failure +azithromycin + metronidazole	2	5 mg/kg - every 2 weeks for first 2 doses then every 6 weeks	1	12	Flexible Sigmoidoscopy (4 months): Endoscopic: erythematous mucosa in sigmoid, normal colon for 40 cm Histologic: Mild active chronic colitis	Patient developed <i>Clostridium difficile</i> colitis then flare of irEC. Treatment: - Infliximab 10 mg/kg - Methylprednisolone 1 mg/kg BID then prednisone 75 mg PO BID followed by a taper - PO vancomycin - Immunotherapy was discontinued	14.5/10.5	- Staging scans after concurrent therapy (12 doses) showed stable disease - Developed retroperitoneal bleed and was transitioned to hospice care
2	Ipilimumab/ Nivolumab Dose: Ipilimumab-1 mg/kg, Nivolumab-240 mg (3 mg/kg) Frequency: combined every 6 weeks (4 doses total) followed by nivolumab alone every 2 weeks	Prednisone 60 mg PO daily>taper	1	5 mg/kg - every 2 weeks for first 2 doses then every 4 weeks	1	3 doses of (Ipilimumab+Nivolumab) and 12 doses of nivolumab alone	Upper endoscopy (3 months): Endoscopic: - Gastric body: localized mild inflammation characterized by erythema and friability - Duodenum: an acquired benign-appearing, intrinsic moderate stenosis was found in the second portion of the duodenum associated with a small erosion Histologic: - Gastric body: lymphocytic involvement of gastric pits - Duodenum: no diagnostic abnormality - Duodenal stricture: ulceration and expansion of lamina propria by mononuclear cells	No	12/7.5	- Staging scans after concurrent therapy (15 doses) showed stable disease and patient continues concurrent therapy - Developed mucositis/stomatitis that is being managed conservatively
3	Ipilimumab Dose: 3 mg/kg Frequency: every 3 weeks	Methylprednisolone 1 mg/kg IV twice daily >taper failure	1	5 mg/kg - every 4 weeks	1	2	Not done	No	6.5/3.5	- Staging scans showed stable bulk of disease after concurrent therapy (2 doses) with

**Table 2** IREC management and outcomes (Continued)

Patient	ICI type/dose	Initial management	Number of steroid tapering attempts	Infliximab Dose-frequency	Doses of infliximab to clinical remission	Doses of ICI concurrently administered with infliximab	Follow up endoscopy on concurrent treatment (months)	Recurrence	# of months of follow-up on ICI/on concurrent therapy	Disease progression/ Follow up
4	Ipilimumab/ Nivolumab Dose: Ipilimumab-3 mg/kg, Nivolumab-1 mg/kg Frequency: combined every 3 weeks	Prednisone 60 mg daily>taper failure	1	5 mg/kg - every 4 weeks	1	3	Upper endoscopy (1 month): Endoscopic/histologic - Stomach: normal/ chronic inactive gastritis - Duodenum Normal/ normal Colonoscopy (1 month): - Sigmoid/transverse colon ulcers: fragments of colonic mucosa with crypt architectural disarray and mildly increased cellularity of the lamina propria. Colonoscopy (3 months) - Colonic mucosa with scattered crypt epithelial apoptosis and minimal crypt architectural distortion	No	5/3	ongoing slight progression in one metastatic lesion in the lung - Developed skin rash (ipilimumab cutaneous toxicity) that was managed successfully with topical steroids - Staging scans showed interval progression of his disease in the chest, abdomen and pelvis.
5	Cemiplimab Dose: 350 mg Frequency: every 3 weeks	Prednisone 60 mg daily>taper failure	1	5 mg/kg - once	1	2	Not done	No	4/2.5	- Staging scans demonstrated interval decrease in the disease burden in the chest and lymph nodes - Patient developed radiation/checkpoint pneumonitis and was treated with high dose oral steroids

### Patient 3

Patient 3 is a 70-year-old woman who was first diagnosed with melanoma at the age of 40 and underwent a surgical resection at the time. At the age of 62, she was diagnosed with recurrent metastatic melanoma to the bone and lungs. Over the past 9 years, she has been treated with multiple surgical resections, adjuvant radiation, adjuvant interferon, and talimogene laherparepvec (TVEC). Next, she was enrolled in two clinical trials and one of them included an anti PD-L1 agent as a part of the treatment regimen but had no response or side effects to either trial. She received eight cycles of pembrolizumab without adverse events but with continued disease progression. Next, she was treated with ipilimumab. Two weeks after the second cycle of ipilimumab, the patient developed diarrhea, vomiting, abdominal pain, and poor oral intake. She was admitted to the hospital and underwent an upper endoscopy that demonstrated patchy gastritis and diffuse active duodenitis with villous blunting (Table 1). A flexible sigmoidoscopy demonstrated no abnormalities grossly and histologically. Based on these findings, she was treated with methylprednisolone 1 mg/kg twice daily to which her symptoms improved but on transitioning to high dose oral glucocorticoids her symptoms recurred and did not respond to another challenge of intravenous steroids. She was administered one dose of infliximab (5 mg/kg) and her steroids were tapered subsequently. Restaging imaging at that point revealed stable disease on ipilimumab. She had been off ICI for 8 weeks due to irEC and it was determined that she would benefit from continued immunotherapy with concurrent infliximab (5 mg/kg every 4 weeks, Table 2). The patient subsequently received 2 cycles of ipilimumab (to complete a total planned course of 4 cycles) with monthly infliximab infusions (total of 4 doses). She had no further diarrhea or abdominal pain through her treatment. While on concurrent therapy, she developed a pruritic skin rash that was biopsied and thought to be a cutaneous manifestation of ipilimumab toxicity. This was managed successfully with topical steroids. Restaging scans after completion of a total of 4 planned cycles of ipilimumab showed stability in the majority of her disease with slight progression in one metastatic lesion in the lung.

### Patient 4

Patient 4 is a 73-year-old man who was diagnosed with metastatic melanoma to the peritoneum and lungs at the age of 72. At diagnosis he was treated with 13 cycles of atezolizumab (anti-PD-L1) and cobimetinib (MEK inhibitor) as well as radiation therapy to the abdomen. He tolerated these therapies well with no adverse events however his disease continued to progress. Next, he was treated with ipilimumab and nivolumab (Table 1). Eleven days after receiving his first cycle, he developed worsening

abdominal pain, nausea, vomiting and decreased oral intake. He underwent an upper endoscopy that demonstrated active gastritis and active duodenitis with villous injury. A flexible sigmoidoscopy showed mucosal ulceration with biopsies demonstrating severe active colitis with ulceration. He was then treated with prednisone 60 mg daily with difficulty tapering due to symptom recurrence. Further doses of ipilimumab and nivolumab were held for a total of 2.5 months. Restaging scans were obtained at the time and showed ongoing progression of disease burden in the abdomen. The severity of his irEC and the risk of colonic perforation prompted the decision to initiate concurrent treatment with infliximab. The patient received three more cycles of ipilimumab and nivolumab with infliximab (5 mg/kg every 4 weeks, Table 2). He had no further diarrhea, abdominal pain, nausea, vomiting, or other manifestation of irAEs. Follow-up upper endoscopy after two doses of concurrent therapy showed chronic inactive gastritis and a normal duodenal mucosa, and a flexible sigmoidoscopy showed a mucosal ulcer that demonstrated crypt architectural disarray but with improvement from previously seen active colitis. A follow up colonoscopy after completion of a total of three doses of concurrent therapy showed scattered crypt epithelial apoptosis and minimal crypt architectural distortion. Staging scans after completion of a total of 4 cycles of ipilimumab and nivolumab (3 of which were on concurrent therapy) demonstrated interval progression of his metastatic disease burden in the chest, abdomen, and pelvis. He is being considered for surgical debulking to reduce the metastatic disease burden in the abdomen.

### Patient 5

Patient 5 is a 79-year-old woman who was diagnosed with a cutaneous squamous cell carcinoma with metastasis to the lungs and lymph nodes. She underwent surgical resection of the primary lesion as well as radiation therapy to involved lymph nodes. Simultaneously, she was treated with cemiplimab (PD-1 inhibitor). Two weeks after receiving the first dose of cemiplimab, she developed significant nausea, vomiting, and diarrhea. She was admitted to the hospital and underwent an upper endoscopy which demonstrated reactive gastropathy and intestinal metaplasia in the gastric mucosa. A flexible sigmoidoscopy was performed and showed increased cellularity of the lamina propria and epithelial injury with focal acute inflammation (Table 1). She was treated with high dose oral glucocorticoids, received a dose of infliximab (5 mg/kg, Table 2), and cemiplimab therapy was held for 6 weeks. Her nausea, vomiting, and diarrhea resolved. Subsequently, she received a total of 2 cycles of cemiplimab without recurrence of her gastrointestinal symptoms. She developed worsening shortness of breath and chest imaging revealed evidence of



pneumonitis. This was thought to be secondary to radiation and exacerbated by immunotherapy. She was treated with prednisone 60 mg that was tapered successfully; however, further cemiplimab doses were held. Restaging scans demonstrated interval decrease in the size of metastatic foci in the lymph nodes and the chest.

## Discussion

The biological rationale for combining anti-TNF $\alpha$  therapies with ICIs comes from recent insights into the role of TNF $\alpha$  in tumor immunology. TNF $\alpha$  produced in the setting of anti-PD-1 blockage leads to impaired CD8+ tumor infiltrating T lymphocyte responses [17]. Additionally, TNF $\alpha$  increases activation-induced cell death in T cells, limiting their viability in the tumor microenvironment [18, 20]. In a mouse model of melanoma, concurrent treatment with anti-PD-1 and anti-TNF $\alpha$  led to improved anti-tumor responses [17]. More recently, in a murine colon cancer model, concurrent treatment with anti-TNF $\alpha$  and combined anti-CTLA-4 and anti-PD-1 improved survival when compared with double checkpoint inhibition treatment alone [18]. When colitis was concomitantly induced in the tumor bearing mice through dextran sodium sulfate (DSS), the mice that received anti-TNF $\alpha$  and double checkpoint inhibition had better colitis amelioration and improved overall survival [18]. By blocking TNF $\alpha$  both studies showed an increase in CD8+ T cells numbers and viability in the tumor microenvironment and draining lymph nodes [17, 18]. These findings add to a growing body of literature that implicates innate inflammation in tumor promotion [21–23].

TNF $\alpha$  plays an essential role in the pathogenesis of irEC. Patients with irEC have up-regulated mucosal TNF $\alpha$  and a local activation of the TNF $\alpha$  gene signature [18]. Additionally, mucosal TNF $\alpha$  levels predict irEC steroid responsiveness with higher mucosal TNF $\alpha$  levels predicting lower steroid responsiveness [24]. Multiple groups have previously reported on treatment of severe irEC with TNF $\alpha$  blockers [8, 14, 15, 25]. However, after receiving anti-TNF $\alpha$ , patients' ICI therapy was usually discontinued. In this case series, we report our institutional experience with patients who received immunotherapy and anti-TNF $\alpha$  concurrently.

Patients 2 and 4 were both treated with a combination of ipilimumab and nivolumab while Patients 1, 3, and 5 received monotherapy with pembrolizumab, ipilimumab, or cemiplimab, respectively. Patients 2, 3, and 4 all received a different ICI months to years prior to the regimen immediately associated with colitis. Given that the irAE to some ICI may manifest up to 2 years after therapy [26], the irEC they experienced may have a mixed component due to previous exposure to multiple ICIs. The onset of symptoms was sooner and the severity was worse in the patients who received a

combination of ipilimumab and nivolumab compared to those receiving a single agent ICI, consistent with findings reported in the literature previously [6, 26].

Patient 1 had a history of segmental colitis associated with diverticulitis (SCAD) prior to initiation of ICI. Overlapping features of ICI and SCAD were seen on the colonic biopsy. The pathophysiology of SCAD is incompletely understood but the syndrome is thought to overlap with IBD [27]. Some retrospective studies reported increased risk of irEC in patients with baseline active inflammatory and autoimmune diseases, placing the patient at a higher risk of irEC [7, 28].

On presentation with symptoms, all patients were initiated on glucocorticoid therapy for irEC and achieved good control. Patients 1, 3, 4, and 5 were unable to maintain symptom control with glucocorticoid tapering. The decision to resume ICI after irEC carries a serious risk of relapse and is often done on an individual basis [29]. Some studies have shown that 50–60% of these patients have relapse of irEC [14, 29]. In one study, after irEC resolution, ICIs were restarted concomitantly with vedolizumab, an  $\alpha 4\beta 7$  integrin inhibitor that blocks T cell trafficking to the gut, only one out of eight patients had recurrence of irEC [14]. Although vedolizumab is a reasonable approach for treatment of glucocorticoid refractory irEC, inhibition of T cell trafficking into the gut may be risky in patients with gastrointestinal malignancies (e.g. patient 2) where antitumor T cells would also require access to the gastrointestinal mucosa. Similarly, vedolizumab could inhibit responses to gastrointestinal metastases, which are found in approximately 5% of patients with melanoma and are often not seen on surveillance imaging [30, 31]. We favor infliximab as initial biologic therapy for irEC for these reasons, as well as the potential antitumor benefit associated with TNF $\alpha$  blockade.

The decision to initiate concurrent ICI and anti-TNF $\alpha$  therapy in our cohort was driven by an inability to taper steroids and concern for irEC recurrence. Infliximab was administered at a dose of 5 mg/kg. The frequency of infliximab infusions varied depending on ICI regimen and irEC severity. In general, patients were loaded on infliximab using standard dosing at weeks 0, 2, and 6. Maintenance therapy frequency was selected based on the assumption that patients receiving ongoing immunotherapy in the setting of irEC would behave like patients with severe IBD, and that they may require more frequent infliximab administration than the standard 8 week interval. In addition, for patient convenience, infliximab was infused on the same schedule as the immunotherapy, with infusions occurring on the same day, though the drugs were not given simultaneously.

After initiation of concurrent anti-TNF $\alpha$  and ICI therapy, all patients continued to receive ICI without

recurrence of symptoms. Follow up endoscopies in Patients 1, 2, and 4 showed resolution of acute inflammatory features. Staging scans in Patients 1, 2, 3, and 5 after concurrent therapy demonstrated overall disease stability. Patient 4 had progression of his disease despite targeted therapy, immunotherapy, and radiation. He is currently being considered for surgical management for symptom control. After receiving anti-TNF $\alpha$  and 12 further doses of ICI with no disease progression, Patient 1 developed a *Clostridium difficile* infection after which he had recurrence of irEC. After treatment with immunotherapies, gastrointestinal disruption (e.g., due to infection) may cause alteration in the gut microbiota and the local immune compartment, resulting in a breach in tolerance leading to irEC [4, 7].

Our experience adds to the growing animal literature showing that concurrent anti-TNF $\alpha$  and ICI therapy is safe, does not negatively impact tumor control and is associated with a better side effect profile. Importantly, patients were able to continue on immunotherapy. We suggest that concurrent anti-TNF $\alpha$  be considered in patients who develop severe irECs early in their immunotherapy course where additional immunotherapy is likely to provide a benefit, and where other treatment alternatives are either unavailable or have a low likelihood of providing benefit. Prospective data will be necessary, however, to clearly define populations where anti-TNF $\alpha$  concurrent with immunotherapy is both safe, and leads to improved tumor outcomes.

An ongoing phase I clinical trial (NCT03293784) is evaluating the safety and tolerability of treating metastatic melanoma with ICIs combined with either infliximab or certolizumab, a similar anti-TNF $\alpha$  agent. Our experience helps provide evidence of the safety of combination treatment with anti-TNF $\alpha$  and ICI, which we propose should accelerate the initiation of a phase II clinical trial to examine the impact of TNF $\alpha$  blockade on both irAEs and antitumor immunity.

#### Acknowledgements

NA

#### Authors' contributions

YRB compiled and reviewed all of the data. JVC, PKB, AP and TSH assessed and confirmed the accuracy of the details relating to the patients' oncologic history and treatment. MD assessed and confirmed the accuracy of the patients' gastroenterological history, treatment, and endoscopy results. YRB and MD wrote the manuscript with contributions from all of the authors. All authors read and approved the final manuscript.

#### Funding

Funding was provided by National Institutes of Health Mentored Clinical Scientist Development Award 1K08DK114563-01 and the American Gastroenterological Association Research Scholars Award (M.D.).

#### Availability of data and materials

Not applicable.

#### Ethics approval and consent to participate

NA

#### Consent for publication

Patient records were accessed and analyzed through a protocol approved by the Partners Institutional Review Board that waved patient consent.

#### Competing interests

J.V.C. has received consulting fees from Sanofi-Genzyme. P.K.B. receives consulting fees from Lilly, Angiochem, Tesaro, Genentech-Roche, speaker's honoraria from Genentech-Roche and Merck and grant funding from Merck and BMS (institutional). A.R.P. is a consultant/advisory board member for Puretech, Driver, Foundation Medicine and Eisai; and has institutional research funding from Array, Plexxikon, Guardant, BMS, MacroGenics, Genentech-Roche, Novartis, OncoMed, and Tolero. T.S.H. receives research funding (Clinical Trials) from BMS, Taiho, Tesaro, IntraOp, Astra-Zeneca, and Novartis, and an advisory board honorarium from Merck. M.D. receives research funding from Novartis, and has received consulting fees from Genentech-Roche and Tillotts. All other authors declare no competing interests.

#### Author details

<sup>1</sup>Department of Medicine, Massachusetts General Hospital, Boston, MA 02114, USA. <sup>2</sup>Harvard Medical School, Boston, MA 02115, USA. <sup>3</sup>Division of Oncology, Department of Medicine, Massachusetts General Hospital, Boston, MA 02114, USA. <sup>4</sup>Department of Radiation Oncology, Department of Medicine, Massachusetts General Hospital, Boston, MA 02114, USA. <sup>5</sup>Division of Gastroenterology, Department of Medicine, Massachusetts General Hospital, Boston, MA 02114, USA.

Received: 27 June 2019 Accepted: 14 August 2019

Published online: 22 August 2019

#### References

- Ribas A, Wolchok JD. Cancer immunotherapy using checkpoint blockade. *Science*. 2018;359:1350–5.
- Wei SC, Duffy CR, Allison JP. Fundamental mechanisms of immune checkpoint blockade therapy. *Cancer Discov*. 2018;8:1069–86.
- Sanmamed MF, Chen L. A paradigm shift in Cancer immunotherapy: from enhancement to normalization. *Cell*. 2018;175:313–26.
- Pauken KE, Dougan M, Rose NR, Lichtman AH, Sharpe AH. Adverse events following Cancer immunotherapy: obstacles and opportunities. *Trends Immunol*. 2019. <https://doi.org/10.1016/j.it.2019.04.002>.
- Postow MA, Sidlow R, Hellmann MD. Immune-related adverse events associated with immune checkpoint blockade. *N Engl J Med*. 2018;378:158–68.
- Geukes Foppen MH, et al. Immune checkpoint inhibition-related colitis: symptoms, endoscopic features, histology and response to management. *ESMO Open*. 2018;3:e000278.
- Soularue E, et al. Enterocolitis due to immune checkpoint inhibitors: a systematic review. *Gut*. 2018;67:2056–67.
- Dougan M. Checkpoint blockade toxicity and immune homeostasis in the gastrointestinal tract. *Front Immunol*. 2017;8:1547.
- Hughes MS, et al. Colitis after checkpoint blockade: a retrospective cohort study of melanoma patients requiring admission for symptom control. *Cancer Med*. 2019. <https://doi.org/10.1002/cam4.2397>.
- Brahmer JR, Lacchetti C, Thompson JA. Management of Immune-Related Adverse Events in patients treated with immune checkpoint inhibitor therapy: American Society of Clinical Oncology clinical practice guideline summary. *J Oncol Pract*. 2018;14:247–9.
- Puzanov I, et al. Managing toxicities associated with immune checkpoint inhibitors: consensus recommendations from the Society for Immunotherapy of Cancer (SITC) toxicity management working group. *J Immunother Cancer*. 2017;5:95.
- Thompson JA, New NCCN. Guidelines: recognition and Management of Immunotherapy-Related Toxicity. *J Natl Compr Cancer Netw JNCCN*. 2018; 16:594–6.
- Haanen JBAG, et al. Management of toxicities from immunotherapy: ESMO Clinical Practice Guidelines for diagnosis, treatment and follow-up. *Ann Oncol Off J Eur Soc Med Oncol*. 2018;29:iv264–6.

14. Abu-Sbeih H, et al. Early introduction of selective immunosuppressive therapy associated with favorable clinical outcomes in patients with immune checkpoint inhibitor-induced colitis. *J Immunother Cancer*. 2019;7:93.
15. Johnson DH, et al. Infliximab associated with faster symptom resolution compared with corticosteroids alone for the management of immune-related enterocolitis. *J Immunother Cancer*. 2018;6:103.
16. Wang Y, et al. Immune-checkpoint inhibitor-induced diarrhea and colitis in patients with advanced malignancies: retrospective review at MD Anderson. *J Immunother Cancer*. 2018;6:37.
17. Bertrand F, et al. TNF $\alpha$  blockade overcomes resistance to anti-PD-1 in experimental melanoma. *Nat Commun*. 2017;8:2256.
18. Perez-Ruiz E, et al. Prophylactic TNF blockade uncouples efficacy and toxicity in dual CTLA-4 and PD-1 immunotherapy. *Nature*. 2019;569:428.
19. Common Terminology Criteria for Adverse Events (CTCAE). 2017;147.
20. Zheng L, et al. Induction of apoptosis in mature T cells by tumour necrosis factor. *Nature*. 1995;377:348–51.
21. Dougan M, et al. A dual role for the immune response in a mouse model of inflammation-associated lung cancer. *J Clin Invest*. 2011;121:2436–46.
22. Ridker PM, et al. Effect of interleukin-1 $\beta$  inhibition with canakinumab on incident lung cancer in patients with atherosclerosis: exploratory results from a randomised, double-blind, placebo-controlled trial. *Lancet Lond Engl*. 2017;390:1833–42.
23. Dougan M, Dranoff G, Dougan SK. Cancer immunotherapy: beyond checkpoint blockade. *Annu Rev Cancer Biol*. 2019;3:55–75.
24. Coutzac C, et al. Colon immune-related adverse events: anti-CTLA-4 and anti-PD-1 blockade induce distinct Immunopathological entities. *J Crohns Colitis*. 2017;11:1238–46.
25. Som A, et al. Immune checkpoint inhibitor-induced colitis: a comprehensive review. *World J Clin Cases*. 2019;7:405–18.
26. Boutros C, et al. Safety profiles of anti-CTLA-4 and anti-PD-1 antibodies alone and in combination. *Nat Rev Clin Oncol*. 2016;13:473–86.
27. Schembri J, Bonello J, Christodoulou DK, Katsanos KH, Ellul P. Segmental colitis associated with diverticulosis: is it the coexistence of colonic diverticulosis and inflammatory bowel disease? *Ann Gastroenterol*. 2017;30:257–61.
28. Menzies AM, et al. Anti-PD-1 therapy in patients with advanced melanoma and preexisting autoimmune disorders or major toxicity with ipilimumab. *Ann Oncol Off J Eur Soc Med Oncol*. 2017;28:368–76.
29. Marthey L, et al. Cancer immunotherapy with anti-CTLA-4 monoclonal antibodies induces an inflammatory bowel disease. *J Crohns Colitis*. 2016;10:395–401.
30. Blecker D, Abraham S, Furth EE, Kochman ML. Melanoma in the gastrointestinal tract. *Am J Gastroenterol*. 1999;94:3427–33.
31. Bello E, Cohen JV, Mino-Kenudson M, Dougan M. Antitumor response to microscopic melanoma in the gastric mucosa mimicking ipilimumab-induced gastritis. *J Immunother Cancer*. 2019;7:41.

## Publisher's Note

Springer Nature remains neutral with regard to jurisdictional claims in published maps and institutional affiliations.

**Ready to submit your research? Choose BMC and benefit from:**

- fast, convenient online submission
- thorough peer review by experienced researchers in your field
- rapid publication on acceptance
- support for research data, including large and complex data types
- gold Open Access which fosters wider collaboration and increased citations
- maximum visibility for your research: over 100M website views per year

**At BMC, research is always in progress.**

Learn more [biomedcentral.com/submissions](https://biomedcentral.com/submissions)

